

Dimethylnitrosamine-induced liver injury in rats: the early deposition of collagen

Joseph George ^a, Keshav Ramesh Rao ^b, Robert Stern ^{c,*},
Gowri Chandrakasan ^a

^a Department of Biochemistry, Central Leather Research Institute, Adyar, Chennai 600 020, India

^b Department of Pathology, Sri Ramachandra Medical College and Research Institute, Porur, Chennai 600 116, India

^c Department of Pathology, School of Medicine, University of California, San Francisco, CA 94143-0506, USA

Received 11 January 2000; accepted 22 September 2000

Abstract

Dimethylnitrosamine (DMN) is a potent hepatotoxin that can cause fibrosis of the liver. Its ability to provide a suitable rapid experimental murine model for early human cirrhosis was examined. The drug was administered to adult male albino rats in order to document sequential pathological and biochemical alterations. Injury was produced by intraperitoneal injections of DMN on three consecutive days of each week over a 3-week period. A rapid increase in collagen content was documented, with linear increases occurring from days 7 to 21. Livers were examined for histopathological changes on days 7, 14 and 21 following the beginning of exposure. Severe centrilobular congestion and haemorrhagic necrosis could be observed on day 7. Centrilobular necrosis and intense neutrophilic infiltration were observed on day 14. By day 21, collagen fiber deposition could be observed, together with severe centrilobular necrosis, with focal fatty changes, bile duct proliferation, bridging necrosis and fibrosis surrounding the central veins. A decrease in total protein and increase in DNA were also documented. DMN-induced liver injury in rats appears to be a potential animal model for early human cirrhosis and the rapid deposition of collagen, and may serve as a convenient procedure for screening antifibrotic agents. © 2001 Elsevier Science Ireland Ltd. All rights reserved.

Keywords: Dimethylnitrosamine; Hepatic fibrosis; Cirrhosis; Liver collagen; Centrilobular necrosis; Apoptosis; Bridging necrosis

1. Introduction

Dimethylnitrosamine (DMN) is a potent hepatotoxin, carcinogen and mutagen (Haggerty and

Holsapple, 1990). Its hepatotoxicity was first reported by Barnes and Magee (1954) following an industrial accident. The toxicity produced by DMN is mediated by its reactive metabolites and not by the parent compound. Its metabolic half-life is < 10 min in rodents and about 20 min in non-human primates (Anderson et al., 1992). DMN targets primarily the liver, which contains

* Corresponding author. Tel.: +1-415-4764961; fax: +1-415-4769672.

E-mail address: rstern@itsa.ucsf.edu (R. Stern).

the necessary enzymes for its metabolic activation. Metabolism in the liver is by a microsomal membrane-bound enzyme, cytochrome P-450IIE1 (Yang et al., 1985, 1990; Yoo et al., 1988). Activation and degradation of DMN produces formaldehyde and methanol, and the alkylating intermediate reacts with nucleic acids and proteins to form methylated macromolecules.

In the rat model, DMN administration causes severe necrosis, but also deposition of extracellular matrix proteins in the liver, particularly collagen (Ala-Kokko et al., 1987; Savolainen et al., 1988). A detailed study on the role of intracellular enzymes in collagen biosynthesis induced by DMN has been reported Risteli and Kivirikko, 1976a,b. Glycoprotein metabolism has also been investigated following DMN treatment (George and Chandrakasan, 1996a). But a comprehensive histopathological investigation of the temporal pathophysiological changes in the liver following sequential administration of DMN has not been carried out previously. The present investigation is aimed at studying such changes during DMN administration using the male albino rat model. We were particularly interested in developing a model for the very early deposition of collagen that might be useful as a rapid tool for screening antifibrotic agents.

2. Materials and methods

2.1. Materials

DMN, L-hydroxyproline, Chloramine-T, deoxyribonucleic acid, diphenylamine, bovine serum albumin, hematoxylin and eosin B were purchased from Sigma Chemical, St. Louis, MO, USA. Ethyl alcohol, formaldehyde and *p*-dimethylaminobenzaldehyde were obtained from E. Merck, Darmstadt, Germany, and ethylene glycol monomethyl ether (methyl cellosolve) from Fluka AG, Switzerland. Trichloroacetic acid (TCA), potassium sodium tartarate and Folin-Ciocalteu's phenol reagent were the products of Loba Chemie, Bombay, India. All other chemicals used were of analytical grade.

2.2. Animals and treatment

Male albino rats of the Wistar strain were approximately 3 months in age, weighing between 180 and 200 g. Animals were bred and maintained in an air-conditioned animal house, with commercial diet (Hindustan Lever, Bombay, India) and water available ad libitum. They were housed in polypropylene cages with a wire mesh top and a hygienic bed of husk.

The DMN was injected intraperitoneally in doses of 1 μ l (diluted 1:100 with 0.15 M sterile NaCl) per 100 g body weight. The injections were given on three consecutive days of each week for a period of 3 weeks. Control animals received the same volume of 0.15 sterile NaCl. Animals were injected without anaesthesia. Treated animals were sacrificed on days 7, 14 and 21 from the beginning of exposure. Some control animals were sacrificed at the beginning of the experiment, and some together with the treated animals on days 7, 14 and 21 and the pooled value was used as control. The control and the 7th day group comprised 12 rats each, while the 14th and 21st day group consisted of nine and seven rats respectively. All rats were anaesthetized with diethyl ether before sacrifice.

The livers were rapidly removed, rinsed in cold saline and weighed in the wet state. A portion of liver was fixed for histopathology, and the remaining tissue stored at -70°C until assayed. The body weight and liver weight of the animals in each group were measured. The morphological and behavioral changes were also monitored after administration of DMN. Ascitic fluid was collected before sacrifice. Body weight was measured only after removal of the ascitic fluid.

2.3. Biochemical analyses

Liver tissue was homogenized in a teflon/glass homogenizer (Remi, Bombay, India) using cold 1.15% KCl solution at 4°C . The final concentration of the homogenate was adjusted to 100 mg tissue/ml. The total protein present in the liver homogenate was determined by the method of Lowry et al. (1951). Bovine serum albumin in 0.1 N NaOH was used as standard.

The DNA present in the liver tissue was extracted by the method of Schneider (1957). In brief, 2 ml of 10% liver homogenate in 1.15% KCl was mixed with 2.5 ml of ice cold 10% TCA and centrifuged at 5000 rpm for 10 min. The sediment was suspended in 2.5 ml of ice cold 10% TCA and centrifuged again. The sediment was then suspended in 5 ml of 95% ethanol at 70°C. It was stirred for 5 min while maintaining the temperature and centrifuged after cooling. This procedure was repeated twice for complete removal of inorganic phosphorus. The residue was suspended in 2.5 ml of 5% TCA and warmed for 15 min at 90°C with occasional stirring. It was centrifuged after cooling and the supernatant was collected. The residue was resuspended in 2.5 ml of 5% TCA and the extraction was repeated. The combined TCA extracts obtained from individual livers constituted the DNA fraction.

The DNA present in the liver extract was estimated according to the method of Burton (1956). In brief, 1 ml of the DNA extract was mixed with 2 ml of diphenylamine reagent and heated in a boiling water bath for 10 min. The optical density was measured at 600 nm spectrophotometrically. DNA standard was prepared from highly polymerized calf thymus DNA.

Total collagen present was determined by estimating the hydroxyproline content, an imino acid characteristic of collagen. Estimation was according to the method of Woessner (1961). A known weight of the fresh liver tissue was hydrolyzed in 6 N HCl (final conc.) in sealed tubes at 110°C for 16 h. The hydrolyzed samples were evaporated to dryness over a boiling water bath to remove acid and the residue dissolved in distilled water and made up to a known volume. It was decolorized with activated charcoal and filtered through Whatman filter paper. For the determination of hydroxyproline, 1 ml of the clear filtrate was mixed with 1 ml of freshly prepared chloramine-T solution and allowed to stand for 20 min. It was then mixed with 1 ml of 3.15 M perchloric acid and incubated for 5 min. Finally, 1 ml of freshly prepared *p*-dimethylaminobenzaldehyde was added, mixed well and placed in a water bath at 60°C for 20 min. Absorbance was measured using a Shimadzu UV-160A spectrophotometer at 560

nm. The total collagen content in the liver tissue was calculated by multiplying the hydroxyproline content by the factor 7.46 as postulated by Neuman and Logan (1950).

Arithmetic mean and standard error were calculated for the biochemical data. The results were statistically evaluated using one-way analysis of variance (ANOVA). The control mean values were compared with the treated mean values on days 7, 14 and 21 of the experiment using the least significant difference method. The value of $P < 0.01$ was considered statistically significant.

2.4. Procedures for histopathology

Immediately after sacrifice, the liver tissue was quickly removed and a portion was instantly fixed in 10% phosphate buffered formalin (prepared by dissolving 3.5 g anhydrous sodium phosphate monobasic and 6.5 g anhydrous sodium phosphate dibasic in 100 ml of 40% formaldehyde and made up to 1 l with water). Fixed liver samples were embedded in paraffin blocks and sections of 5 μ m were prepared. Sections were stained with hematoxylin and eosin (H&E) or with Mallory trichrome stain and examined under a Nikon Labophot microscope (Nikon Corporation, Marunouchi 3-chome, Chiyoda-ku, Tokyo 100, Japan).

3. Results

3.1. Behavioral changes, food consumption, and mortality rates

There were no morphological or behavioral changes up to the 10th day of DMN treatment. Treated animals then began exhibiting behavioral changes. Grooming no longer occurred. Food and water intake was much decreased. Extreme lethargy and prostration were observed in the later stages of treatment. Animals exhibited piloerection suggesting extreme sensitivity to ambient temperature. Eyes were pale, and some animals had labored respiration.

None of the rats died in the 7-day treatment group. Among the 14th day group of animals,

25% of the rats died and by the 21st day, the death rate was 42%. The study could not be prolonged because of the marked mortality rate after day 21.

3.2. Gross postmortem examination, body and liver weights

Postmortem examination revealed massive hepatic necrosis. Up to 40% decrease in body weight and 60% decrease in liver weight were recorded. Animals were also jaundiced. Heart, kidney, lungs and spleen were pale, and enlargement of kidney and spleen were also evident. Livers were hard and granular, reduced in size, with diffuse hyperemia. The lobes were partially fused with strictures and nodulation.

Ascites was not present in rats sacrificed on the

seventh day. Ascites was present in all animals however that died during the course of treatment. Among rats sacrificed on the 14th day, ascites was present in 40%, and on the 21st day, in 70% of animals. The volume of ascitic fluid ranged from 10 to 60 ml, with maximum volume observed in the 21st day group.

The percentage changes in liver weight and body weight of the animals during DMN treatment are shown in Fig. 1. A significant decrease in body weight ($P < 0.001$) was observed only on the 14th and 21st day of DMN treatment. In control animals, the mean liver weight was 43.6 mg/g body weight. On the 7th day of DMN administration, the liver weight increased, up to 49.6 mg/g body weight, but it then decreased, with a maximum decrease on the 21st day (24.89 mg/g body weight).

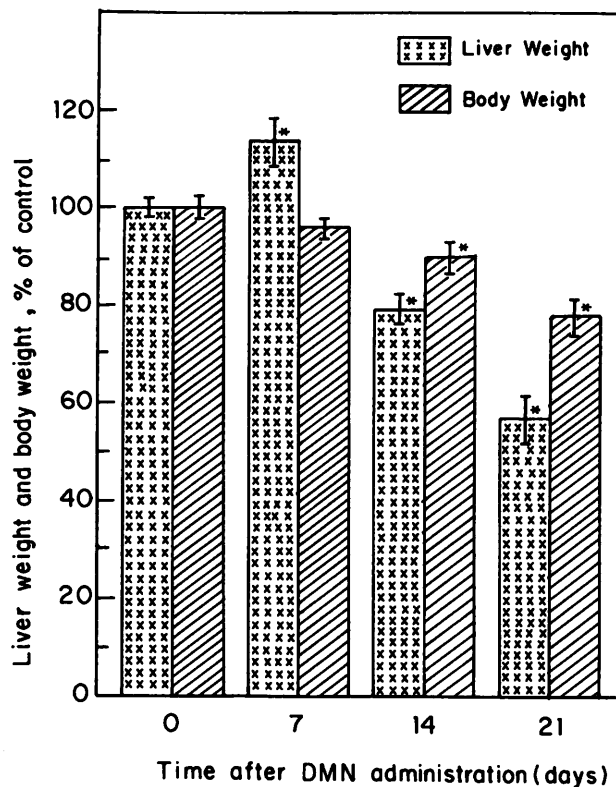


Fig. 1. Percentage changes in liver weight and body weight of animals during DMN-treatment. The values given are mean and standard deviation (* $P < 0.001$ by ANOVA).

Table 1

Total protein, DNA and collagen content in the liver during DMN-induced liver injury in rats^a

Parameters assayed	Control (n = 12)	Day 7 (n = 12)	Day 14 (n = 9)	Day 21 (n = 7)
Protein	165.45 ± 3.86	130.12 ± 4.48*	141.86 ± 6.12*	134.56 ± 5.42*
DNA	2.58 ± 0.13	3.06 ± 0.15**	3.65 ± 0.18*	3.85 ± 0.21*
Collagen	0.98 ± 0.04	1.77 ± 0.06*	2.65 ± 0.09*	3.73 ± 0.15*

^a All values are expressed as mg/g liver wet weight. Values are mean ± standard errors.* $P < 0.001$.** $P < 0.01$ (by ANOVA).

3.3. Biochemical alterations, including collagen, DNA, and protein

Protein and DNA contents of these livers was performed to provide reasonable denominators for the predicted increase in total collagen deposition in the course of the reaction to toxic liver injury. The total protein content in the liver during DMN administration is shown in Table 1. The protein content was significantly reduced ($P < 0.001$) in liver tissue on all days after DMN treatment. (Fig. 1). The effect of DMN on liver DNA is demonstrated in Table 1. When compared to control values, a significant increase ($P < 0.001$) was observed in DNA content on the 7th, 14th and 21st days following administration of DMN.

Total collagen content in the liver was markedly increased ($P < 0.001$) on all the days of DMN administration (Table 1). There was a linear increase in collagen content in the liver between the beginning of DMN-treatment up to day 21, the last day of observations. The increase on the 21st day was about 4-fold compared to untreated control values.

3.4. Histopathology

The control livers showed normal lobular architecture with central veins and radiating hepatic cords. After 7 days of DMN treatment, there was diffuse centrilobular congestion with marked dilatation of central veins. Extensive necrosis and haemorrhage were prominent at this early stage. Mild bile duct hyperplasia was also observed. In two cases, there was centrilobular necrosis (Fig. 2(A)) with marked neutrophilic and mononuclear

cell infiltrates (Fig. 2(B)). After 14 days, centrilobular necrosis was present uniformly with the attendant neutrophil and mononuclear cell infiltrates. Mild bile duct hyperplasia was evident. The 21-day specimens demonstrated many changes frequently observed in human alcoholic cirrhosis. There was centrilobular necrosis with collapse. Hydropic and focal fatty changes were observed as well (Fig. 2(C)). Apoptosis-like changes and dysplasia were frequent (Fig. 2(D)), as well as fibrosis. The extent of fibrosis was further documented using Mallory trichrome staining of the 21-day livers. Accumulation of

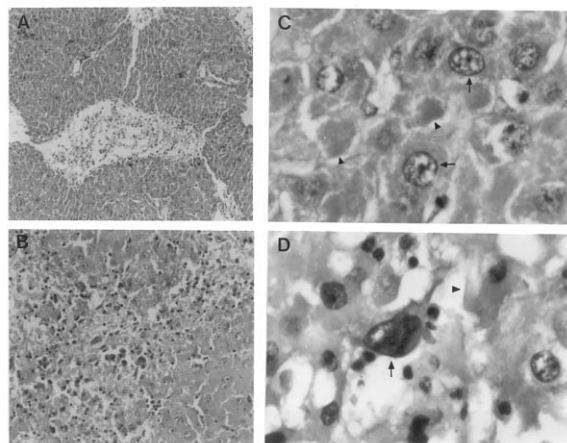


Fig. 2. H&E-stained sections of rat liver following varying lengths of DMN treatment. (A) DMN, 7 days. Centrilobular hepatocyte necrosis and dilatation of central veins (40 ×). (B) DMN, 14 days. Centrilobular hepatocyte necrosis and neutrophilic infiltration (100 ×). (C) DMN, 21 days. Eosinophilic debris (arrow-head) within cytoplasm of hepatocytes, and enlarged hepatocyte nuclei suggestive of regeneration (arrow) (400 ×). (D) DMN 21 days. Apoptotic (arrow-head) and dysplastic (arrow) liver cells (400 ×).

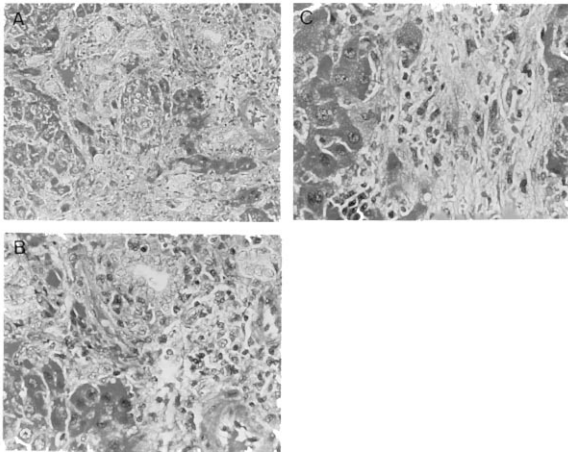


Fig. 3. Mallory trichrome-stained rat liver sections following 21 days of DMN treatment. (A) Bridging necrosis and early fibrosis between central vein and portal tract (100 \times). (B) Fibrosis with bile duct proliferation (150 \times). (C) Bridging fibrosis with collagen fiber deposition (200 \times).

smudged eosinophilic material could be seen (Fig. 2(C)), suggestive of Mallory's hyaline.

There was bridging necrosis and early fibrosis between portal tract and central veins (Fig. 3(A)). All the 21st day liver sections demonstrated fibrosis with well-formed collagen fibers around central veins, as well as duplicated bile ducts (Fig. 3(B)). A higher magnification (200 \times) of the bridging necrosis and fibrosis is presented in Fig. 3(C), in contrast to the 100 \times shown in Fig. 3A.

4. Discussion

In this model of toxic liver injury, an apparent loss of total protein was observed (Fig. 1). The maximum decrease was on day 7 as per the liver wet weight ratio. The decrease of total protein (Table 1) corroborates a previous report (Ala-Kokko et al., 1987). A general inhibition of protein synthesis has been reported after DMN administration in rat liver (Magee, 1958; Heath, 1962) that may be partly responsible for diminished protein levels. The proteins measured are predominantly non-collagenous proteins. The synthesis of collagenous proteins occurs in proliferating non-hepatic (Ito) cells during the process of fibrosis (Weiner et al., 1992; Gressner, 1995).

This apparent decrease may not have been entirely due to a true decrease in the absolute amount of liver protein, but could rather be attributed to significant increases in total liver weight observed on day 7. Edema is one of the five cardinal signs associated with acute inflammation, and is the basis of the swelling and increase in total liver weight at this early time point. Enhanced hyaluronan deposition and its associated water of hydration appears to be associated with this increase in liver size (manuscript in preparation).

Accumulation of connective tissue proteins, especially collagen, have been reported in DMN-induced liver injury (Ala-Kokko et al., 1987; George and Chandrakasan, 1996b). Of particular importance however, is that enhanced collagen could be detected here from the very onset of DMN treatment, with an 81% increase in collagen content on day 7, the first time point at which measurements were made. There was a linear increase in collagen throughout the period of DMN administration, with a nearly 4-fold increase observed in total collagen content by day 21 (Table 1).

Ito cells are primarily responsible for the increased collagen synthesis in the injured liver (Weiner et al., 1992; Gressner and Bachem, 1992). During hepatic necrosis, these cells become activated (Burt, 1993). The activated Ito cells behave like myofibroblasts, and initiate vigorous collagen synthesis (Tanaka et al., 1991; Enzan et al., 1995). No specific identification of Ito cells were made in the present study, but the enhanced collagen deposition is presumed to reflect increased Ito cell activity. The decreased synthesis of collagenolytic enzymes by the impaired hepatocytes may have further contributed to the accumulation of collagen in these liver.

DMN is a particularly potent hepatotoxin. Doses as small as 20 mg/kg cause massive liver necrosis and death in many species (Hashimoto et al., 1989). Exposure to repeated lower doses of DMN causes subacute and chronic liver injury with varying degrees of necrosis, fibrosis and nodular regeneration (Magee and Barnes, 1967). DMN occurs in trace amounts in tobacco smoke condensates (Rhoades and Johnson, 1972; Mc-

Cormick et al., 1973) and may be involved in the etiology of lung cancer. The carcinogenicity of DMN is also well established (Magee, 1989; Magee and Barnes, 1967; Tsutsumi et al., 1993).

DMN-induced liver injury in rats is a reproducible and potentially valuable animal model for studying human hepatic cirrhosis. The histopathological changes observed correlate with the alterations observed in human alcoholic cirrhosis. After 21 days, massive centrilobular necrosis was observed with well developed fibrosis surrounding central veins. Occasional bridging was also found. The mortality rate observed in the present study is consistent with previous reports (Jenkins et al., 1985; Chowdhury and Taylor, 1989). Increased portal pressure and decreased liver blood flow as well as ascites have been reported previously following DMN administration in rats (Jenkins et al., 1985).

An increase in liver weight was observed by the 7th day of DMN treatment (Fig. 1) as is often observed clinically in the early stages of cirrhosis. A significant decrease in liver weight then occurred, as has also been reported (Chowdhury and Taylor, 1989), with a decreased liver weight to body weight ratio (Ala-Kokko et al., 1987). Detoxification of DMN takes place in the liver by the microsomal cytochrome P-450IIE1 group of enzymes (Yang et al., 1985, 1990; Yoo et al., 1988; Tsutsumi et al., 1993). In this connection, it is important to note that an induction of liver enzymes, especially the synthesis of cytochrome P-450IIE1 enzyme systems, is observed in ethanol-treated rats (Tsutsumi et al., 1993). An induction of cytochrome P-450IIE1 enzyme activity is also observed in human liver following ethanol ingestion, with a corresponding increase in encoding mRNA levels (Takahashi et al., 1993). An induction of liver activity, especially the synthesis of cytochrome P-450II group of drug metabolizing enzyme systems, is also observed in phenobarbitone-treated animals (Bhat and Padmanaban, 1979; Kumar and Padmanaban, 1980; Lake et al., 1993). However in the later stages, liver weight is reduced because of decreased protein synthesis, massive cell necrosis and collapse of liver parenchyma. The relative starvation of the experimental animals may

have also contributed to the decrease in liver weight.

Centrilobular necrosis is characteristic of toxic liver injury. Fatty degeneration and centrilobular necrosis are reported in carbon tetrachloride (Kawasaki et al., 1994) and in ethanol-induced liver injury (Caulet et al., 1989; Inomata et al., 1987). Centrilobular hemorrhagic necrosis and mononuclear infiltration are also observed in DMN-induced liver damage (Butler and Hard, 1971; Jezequel et al., 1989). In the present study, severe centrilobular congestion and centrilobular necrosis with intense neutrophilic infiltration were present uniformly by day 14 of DMN administration. Mallory bodies are a key feature of alcoholic liver disease (Vyberg and Leth, 1991; Charels and Kloppel, 1991). Such changes in hepatocytes are considered a histologic marker of alcohol-induced liver damage (McCormick et al., 1973). In the DMN-induced liver injury model reported here, classic Mallory bodies were not observed, though there was the accumulation of intracellular smudged eosinophilic material (Fig. 2(E)) suggestive of Mallory's hyaline, though no such staining was observed within viable cells.

Apoptosis is considered a mechanism for cell death in DMN-induced liver injury (Neuman and Logan, 1950; Hirata et al., 1989). In the present investigation, changes suggestive of apoptosis were observed. Apoptosis occurs not only during normal tissue modifications (Kerr et al., 1972; Cohen, 1994), but also in many pathological processes. It is characterized by cell shrinkage with hyperchromatic nuclear fragmentation, and biochemically, by chromatin cleavage into nucleosomal oligomers (Trump and Berezsky, 1992; Bufa et al., 1993; Savolainen et al., 1988). The DMN-induced liver injury in rats described here was associated with apoptosis, similar to that found in human beings with hepatic fibrosis and alcoholic cirrhosis. An increase in the number of apoptotic bodies are reported in alcoholic liver disease (Yacoub et al., 1995; Goldin et al., 1993) indicating that apoptosis may also be the mode of cell death in ethanol-induced liver damage.

Dysplasia is a premalignant change of hepatocytes characterized by enlargement and multinu-

cleation, nuclear hyperchromatism and multiple nucleoli. The condition is associated with cirrhosis, liver cell carcinoma and viral hepatitis. Dysplasia is common in experimental animals during the induction of liver tumors by chemical carcinogens. In the present investigation some degree of dysplasia was observed on the 21st day of DMN administration.

Bridging necrosis is an indication of severe liver damage, and is associated with poor prognosis (Cooksley et al., 1986; Trump and Berezsky, 1992). The necrosis and bridging fibrosis in DMN-induced liver injury is consistent with such severe liver damage. The liver necrosis found in many of the animals causes collapse of the parenchymal framework of the liver, which histologically can resemble fibrotic changes. However, trichrome staining indicated that new collagen bundles were being deposited, as was confirmed by the biochemical analyses.

In conclusion, DMN induced liver injury in rats reflects changes that occur in human hepatic fibrosis, and displays many of the features, such as portal hypertension, ascites, as well as a number of other histopathological and biochemical abnormalities. Of major importance however is that this is a model for the early onset of collagen deposition, the major protein of the fibrosis and key to the process of cirrhosis. It is an appropriate animal model for studying mechanisms of hepatic fibrosis, and may provide a model for the rapid screening antifibrotic agents.

Acknowledgements

This work was supported by the Indian Council of Medical Research, New Delhi by grant (No. 3/1/2/3/(9201540)/92-NCD-III) to one of the authors (JG). The authors are grateful to Dr. T. Ramasami, Director, Central Leather Research Institute, Madras for his support and interest in this work. The assistance of Dr. A. Sundararaj and Dr. A. Thanikachalam, Department of Pathology, Madras Veterinary College, Madras for histopathological preparations is sincerely acknowledged.

References

- Ala-Kokko, L., Pihlajaniemi, T., Myers, J.C., Kivirikko, K.I., Savolainen, E.R., 1987. Gene expression of type I, III and IV collagens in hepatic fibrosis induced by dimethylnitrosamine in the rat. *Biochem. J.* 244, 75–79.
- Anderson, L.M., Koseniauskas, R., Burak, E.S., Moskal, T.J., Gombar, C.T., Phillips, J.M., Sansone, E.B., Keimig, S., Magee, P.N., Rice, J.M., Harrington, G.W., 1992. Reduced blood clearance and increased urinary excretion of *N*-nitrosodimethylamine in patas monkeys exposed to ethanol or isopropyl alcohol. *Cancer Res.* 52, 1463–1468.
- Barnes, J.M., Magee, P.N., 1954. Some toxic properties of dimethylnitrosamine. *Br. J. Industr. Med.* 11, 167–174.
- Bhat, K.S., Padmanaban, G., 1979. Studies on the biosynthesis of cytochrome P-450 in rat liver. A probe with phenobarbital. *Arch. Biochem. Biophys.* 198, 110–116.
- Bufa, L.M., Eigenbrodt, M.L., Eigenbrodt, E.H., 1993. Apoptosis and necrosis: basic types and mechanisms of cell death. *Arch. Pathol. Lab. Med.* 117, 1208–1214.
- Burt, A.D., 1993. Cellular and molecular aspects of hepatic fibrosis. *J. Pathol.* 170, 105–114.
- Burton, K., 1956. A study of the conditions and mechanism of the diphenylamine reaction for the calorimetric estimation of deoxyribonucleic acid. *Biochem. J.* 62, 315–323.
- Butler, W.H., Hard, G.C., 1971. Hepatotoxicity of dimethylnitrosamine in the rat with special reference to veno-occlusive disease. *Exp. Mol. Pathol.* 15, 209–219.
- Calet, S., Fabre, M., Schoevaert, D., Lesty, C., Meduri, G., Martin, E., 1989. Quantitative study of centrolobular hepatic fibrosis in alcoholic disease before cirrhosis. *Virchows Arch.* 416, 11–17.
- Charels, K., Kloppel, G., 1991. Pathology and pathogenesis of toxic (alcoholic) liver disease. *Hepatogastroenterology* 38, 189–194.
- Chowdhury, S.A., Taylor, R., 1989. Insulin sensitivity in experimental cirrhosis. *Mol. Cell Biochem.* 89, 69–72.
- Cohen, J.J., 1994. Apoptosis: physiologic cell death. *J. Lab. Clin. Med.* 124, 761–765.
- Cooksley, W.G., Bradbear, R.A., Robinson, W., Harrison, M., Halliday, J.W., Powell, L.W., Ng, H.S., Seah, C.S., Okuda, K., Scheuer, P.J., 1986. The prognosis of chronic active hepatitis without cirrhosis in relation to bridging necrosis. *Hepatology* 6, 345–348.
- Enzan, H., Himeno, H., Iwamura, S., Saibara, T., Onishi, S., Yamamoto, Y., Miyazaki, E., Hara, H., 1995. Sequential changes in human Ito cells and their relation to postnecrotic liver fibrosis in massive and submassive hepatic necrosis. *Virchows Arch.* 426, 95–101.
- George, J., Chandrakasan, G., 1996a. Glycoprotein metabolism in dimethylnitrosamine induced hepatic fibrosis in rats. *Int. J. Biochem. Cell Biol.* 28, 353–361.
- George, J., Chandrakasan, G., 1996b. Molecular characteristics of dimethylnitrosamine induced fibrotic liver collagen. *Biochim. Biophys. Acta* 1292, 215–222.
- Goldin, R.D., Hunt, N.C., Clark, J., Wickramasinghe, S.N., 1993. Apoptotic bodies in a murine model of alcoholic

- liver disease: reversibility of ethanol-induced changes. *J. Pathol.* 171, 73–76.
- Gressner, A.M., 1995. Cytokines and cellular crosstalk involved in the activation of fat-storing cells. *J. Hepatol.* 22 (Suppl. 2), S28–S36.
- Gressner, A.M., Bachem, M.G., 1992. Parasinusoidal lipocytes. Their contribution to hepatic connective tissue synthesis and to the mechanisms of matrix amplification in fibrogenesis. In: Clement, B., Guillouzo, A., Libbey, J., Cellular and Molecular Aspects of Cirrhosis. IN-SERM, pp. 157–168.
- Haggerty, H.G., Holsapple, M.P., 1990. Role of metabolism in dimethylnitrosamine induced immunosuppression: a review. *Toxicology* 63, 1–23.
- Hashimoto, N., Ishikawa, Y., Utsunomiya, J., 1989. Effects of portacaval shunt, transposition and dimethylnitrosamine induced chronic liver injury on pancreatic hormones and amino acids in dog. *J. Surg. Res.* 46, 35–40.
- Heath, D.F., 1962. The decomposition and toxicity of dialkyl nitrosamines in rats. *Biochem. J.* 85, 72–91.
- Hirata, K., Ogata, I., Ohta, Y., Fujiwara, K., 1989. Hepatic sinusoidal cell destruction in the development of intravascular coagulation in acute liver failure of rats. *J. Pathol.* 158, 157–165.
- Inomata, T., Rao, G.A., Tsukamoto, H., 1987. Lack of evidence for increased lipid peroxidation in ethanol induced centrilobular necrosis of rat liver. *Liver* 7, 233–239.
- Jenkins, S.A., Grandison, A., Baxter, J.N., Day, D.W., Taylor, I., Shieldsm, R., 1985. A dimethylnitrosamine induced model of cirrhosis and portal hypertension in the rat. *J. Hepatol.* 1, 489–499.
- Jezequel, A.M., Mancini, R., Rinaldesi, M.L., Ballardini, G., Fallani, M., Bianchi, F., Orlandi, F., 1989. Dimethylnitrosamine induced cirrhosis. Evidence for an immunological mechanism. *J. Hepatol.* 8, 42–52.
- Kawasaki, H., Murawaki, Y., Yamada, S., Yamamoto, T., 1994. Toxic cirrhosis. *Nippon Rinsho* 52, 33–39.
- Kerr, J.F.R., Wyllie, A.H., Currie, A.R., 1972. Apoptosis – a basic biological phenomenon with wide ranging implications in tissue kinetics. *Br. J. Cancer.* 26, 239–257.
- Kumar, A., Padmanaban, G., 1980. Studies on the synthesis of cytochrome P-450 and cytochrome P-448 in rat liver. *J. Biol. Chem.* 255, 522–525.
- Lake, B.G., Beaman, J.A., Japenga, A.C., Renwick, A., Davies, S., Price, R.J., 1993. Induction of cytochrome P-450 dependent enzyme activities in cultured rat liver slices. *Food Chem. Toxicol.* 31, 377–386.
- Lowry, O.H., Rosebrough, N.J., Farr, A.L., Randall, R.J., 1951. Protein measurement with the folin phenol reagent. *J. Biol. Chem.* 193, 265–275.
- Magee, P.N., 1958. Toxic liver injury: inhibition of protein synthesis in rat liver by dimethylnitrosamine in vivo. *Biochem. J.* 70, 606–611.
- Magee, P.N., Barnes, J., 1967. Carcinogenic nitroso compounds. *Adv. Cancer Res.* 10, 163–246.
- Magee, P.N., 1989. The experimental basis for the role of nitroso compounds in human cancer. *Cancer Surveys* 8, 207–239.
- McCormick, A., Nicholson, M.J., Baylis, M.A., Underwood, J.G., 1973. Nitrosamines in cigarette smoke condensate. *Nature* 24, 237–238.
- Neuman, R.E., Logan, M.A., 1950. The determination of collagen and elastin in tissues. *J. Biol. Chem.* 186, 549–556.
- Risteli, J., Kivirikko, K.I., 1976a. Intracellular enzymes of collagen biosynthesis in rat liver as a function of age and in hepatic injury induced by dimethylnitrosamine. Changes in prolyl hydroxylase, lysyl hydroxylase, collagen galactosyltransferase and collagen glucosyltransferase activities. *Biochem. J.* 158, 361–367.
- Risteli, J., Kivirikko, K.I., 1976b. Intracellular enzymes of collagen biosynthesis in rat liver as a function of age and in hepatic injury induced by dimethylnitrosamine. Purification of rat prolyl hydroxylase and comparison of changes in prolyl hydroxylase activity with changes in immunoreactive prolyl hydroxylase. *Biochem. J.* 158, 369–376.
- Rhoades, J.W., Johnson, D.E., 1972. *N*-Dimethylnitrosamine in tobacco smoke condensate. *Nature* 236, 307–308.
- Savolainen, E.R., Brocks, D., Ala-Kokko, L., Kivirikko, K.I., 1988. Serum concentrations of the *N*-terminal propeptide of type III procollagen and two type IV collagen fragments and gene expression of the respective collagen types in liver in rats with dimethylnitrosamine-induced hepatic fibrosis. *Biochem. J.* 249, 753–757.
- Schneider, W.C., 1957. Determination of nucleic acids in tissues by pentose analysis. In: Colowick, S.P., Kaplan, N.O. (Eds.), *Methods in Enzymology*, vol. 3. Academic Press, New York, pp. 680–684.
- Takahashi, T., Lasker, J.M., Rosman, A.S., Lieber, C.S., 1993. Induction of cytochrome P-450E1 in the human liver by ethanol is caused by a corresponding increase in encoding messenger RNA. *Hepatology* 17, 236–245.
- Tanaka, Y., Nouchi, T., Yamane, M., Irie, T., Miyakawa, H., Sato, C., Marumo, F., 1991. Phenotypic modulation in lipocytes in experimental liver fibrosis. *J. Pathol.* 164, 273–278.
- Trump, B.F., Berezsky, I.K., 1992. The role of cytosolic calcium in cell injury, necrosis and apoptosis. *Curr. Opin. Cell Biol.* 4, 227–232.
- Tsutsumi, M., Matsuda, Y., Takada, A., 1993. Role of ethanol-inducible cytochrome P-450E1 in the development of hepatocellular carcinoma by the chemical carcinogen, *N*-nitrosodimethylamine. *Hepatology* 18, 1483–1489.
- Vyberg, M., Leth, P., 1991. Ubiquitin: an immunohistochemical marker of Mallory bodies and alcoholic liver disease. *APMIS* 23 (Suppl.), S46–S52.
- Weiner, F.R., Shah, A., Biempica, L., Zern, M.A., Czaja, M.J., 1992. The effects of hepatic fibrosis on Ito cell gene expression. *Matrix* 12, 36–43.
- Woessner, J.F., Jr, 1961. The determination of hydroxyproline in tissue and protein samples containing small proportions of this imino acid. *Arch. Biochem. Biophys.* 93, 440–447.
- Yacoub, L.K., Fogt, F., Griniuviene, B., Nanji, A.A., 1995.

- Apoptosis and bcl-2 protein expression in experimental alcoholic liver disease in the rat. *Alcohol Clin. Exp. Res.* 19, 854–859.
- Yang, C.S., Tu, Y.Y., Koop, D.R., Coon, M.J., 1985. Metabolism of nitrosamines by purified liver cytochrome P-450. *Cancer Res.* 45, 1140–1145.
- Yang, C.S., Yoo, J.S.H., Ishizaki, H., Hong, J., 1990. Cytochrome P-450IIE1: role in nitrosamine metabolism and mechanisms of regulation. *Drug Metab. Rev.* 22, 147–159.
- Yoo, J.S.H., Guengerich, F.P., Yang, C.S., 1988. Metabolism of *N*-nitrosodialkylamines by human liver microsomes. *Cancer Res.* 48, 1499–1504.